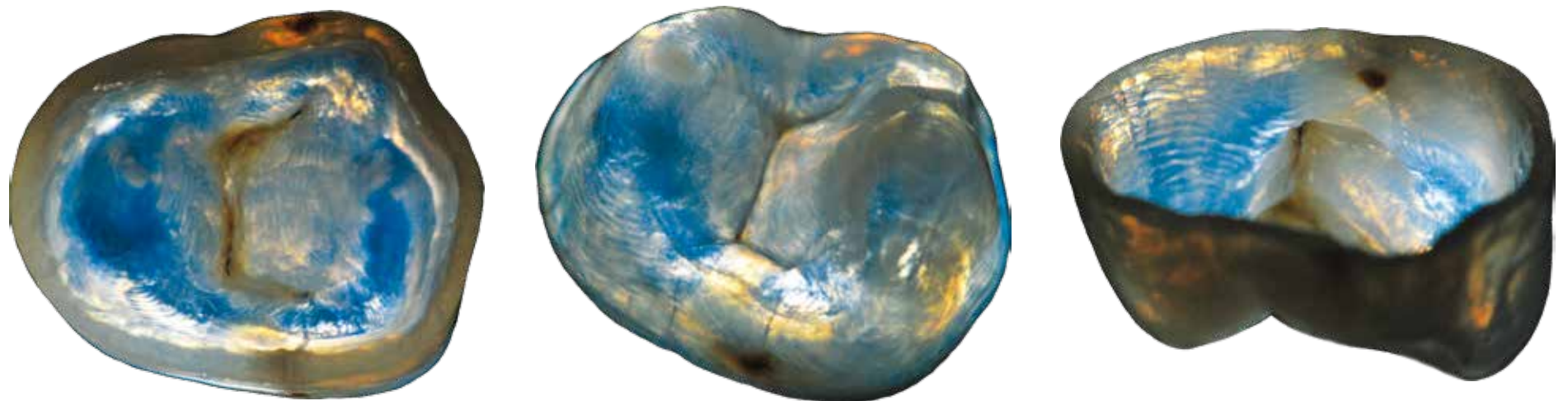
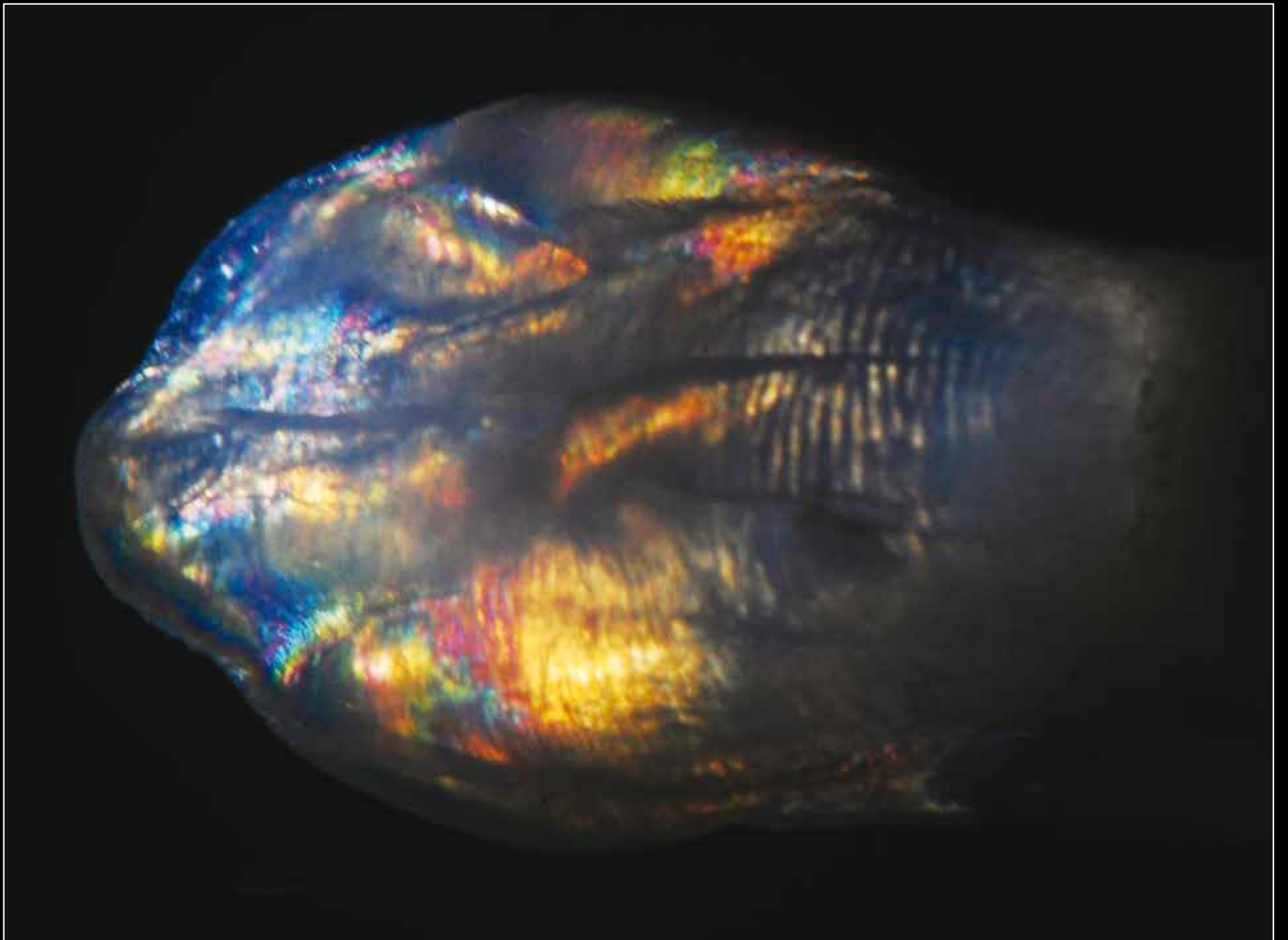
inspiration

people, teeth and restorations

luiznarcisobaratieri & cols





restoration of anterior teeth

direct technique case 4

This case shows the restoration of anterior teeth as a part of a multidisciplinary process that involved orthodontic treatment, orthognatic surgery, periodontal surgery and restorative procedures.

Figures 1 to 4 show the patient's face and mouth (in detail) at rest and smiling. At this stage the patient was undergoing orthodontic treatment for teeth repositioning. Note the size of the teeth and the visible zone of gingiva (Figures 5 to 8). Figures 9 to 10 highlight the lack of proportion between teeth length and width and between reference lines of the patient's face. In order to correct such severe vertical skeletal discrepancy of the upper jaw and ultimately address the harmony of the smile, a orthognatic surgery was conducted with the purpose of reducing the vertical dimensions of the visible gingiva. Figures 11 and 12 show the patient at rest before and after orthognatic surgery, respectively. Observe the difference between incisal lines taking the lips as references. Now observe the same relations in Figures 13 and 14 during the smile. Figures 15 and 16

show the occlusal relations after surgery.

Although after orthognatic surgery the facial proportions were corrected, teeth length and width still remained disproportionate. Since the vertical overlap in occlusion was appropriate, the gain in teeth length could not be achieved only by adding composite resins to the incisal edge of the anterior teeth. Therefore, the increase in teeth length was planned through periodontal plastic surgery. Using a digital calliper, the desired length of the anterior teeth was outlined on a stone model, and a wax-up with the teeth new dimensions was built (Figures 17 and 18).

Using an impression material, a silicon impression of the waxed-up model was made in order to produce a mock-up with acrylic resin (Figure 19). This mock-up served as a surgical guide for the incisions during the gingivoplasty (Figure 20 to 22). After the gingival margins were determined with the incisions, the bone level was brought up to 3 mm apically. After 9 months of surgery the gingival marginal level is stable enough to continue

with the next stage of treatment (Figures 23 and 24). Before beginning with the restorative procedures the shade of the teeth were adjusted through in-office bleaching.

A new stone model was produced and the changes in form were waxed-up to allow the fabrication of a new silicon index (Figure 25). Try-in restoration were produced to select the proper composite shades and evaluate the effect of the new tooth length on speech (Figures 26 to 30). After the shape and shade were adjusted, the restorative procedures could begin. The sequence from Figures 31 to 49 show the adhesive, restorative and finishing procedures. After the restorations were finished, rubber points and felt disks with polishing pastes were used for final luster (Figures 50 to 52). Observe the final aspect of the restorations and compare it with the clinical aspect before treatment (Figures 53 to 66).



Figure 1.

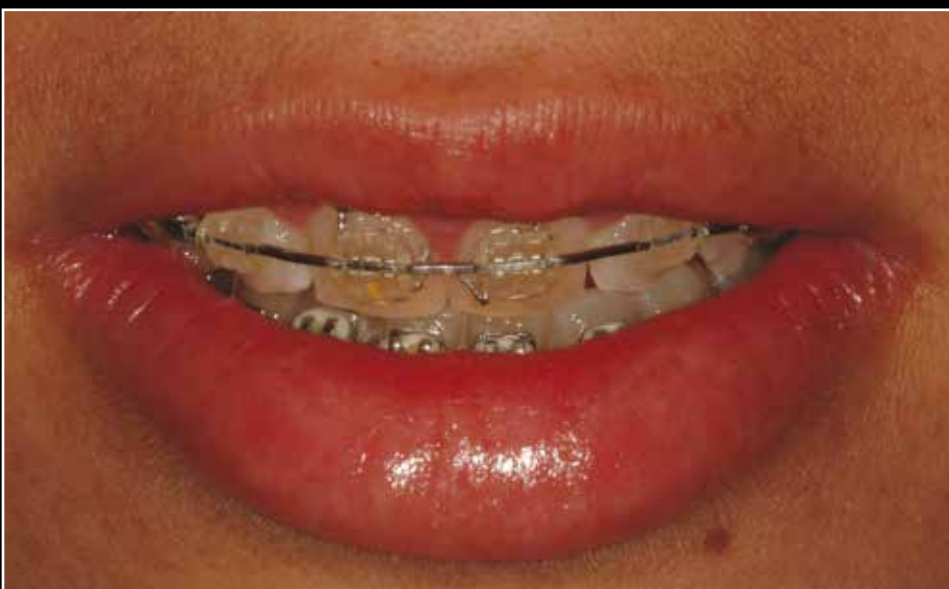
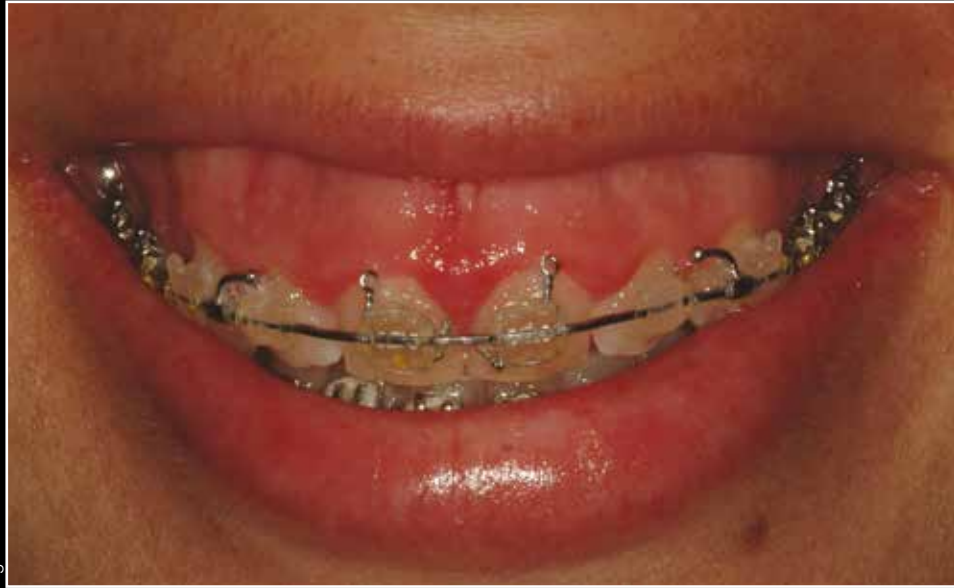
Figure 2.

Figure 3.



Figure 4.



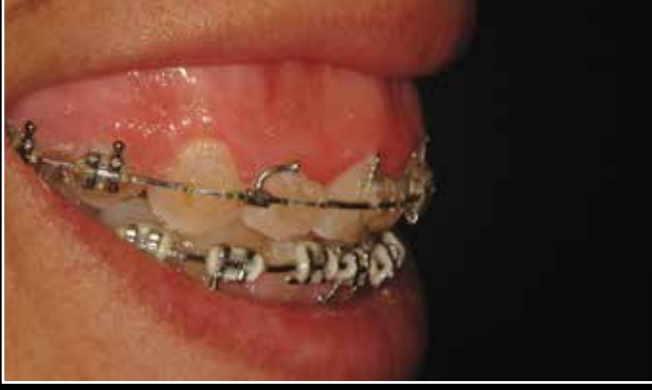

Figure 5.

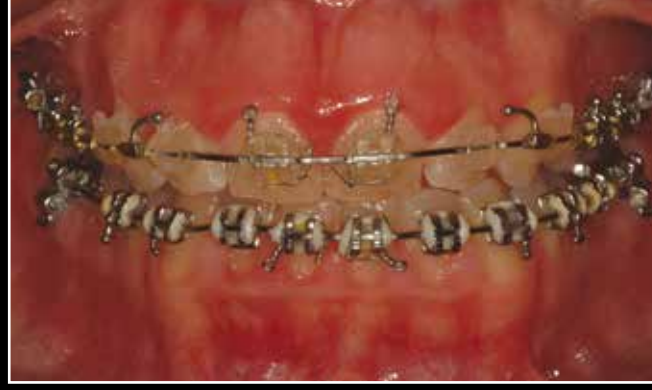

Figure 6.

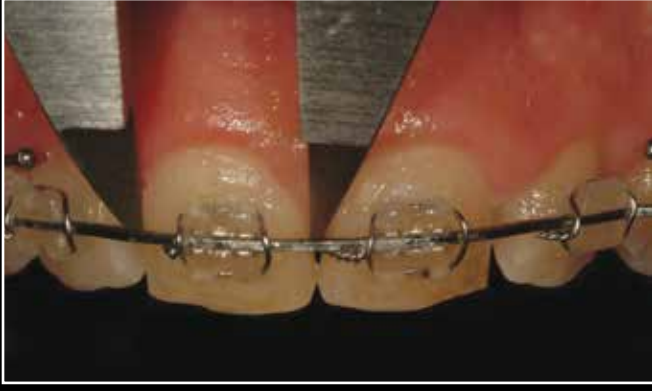

Figure 7.

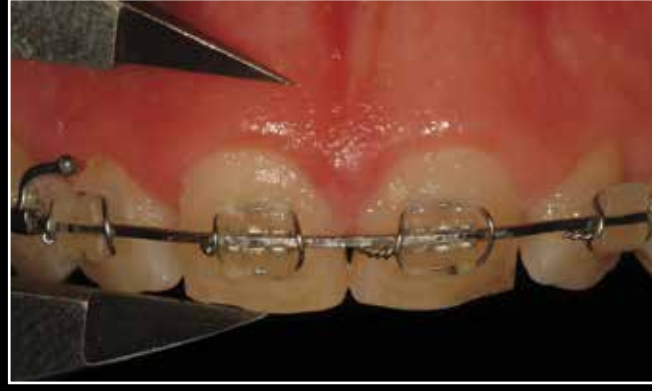

Figure 8.

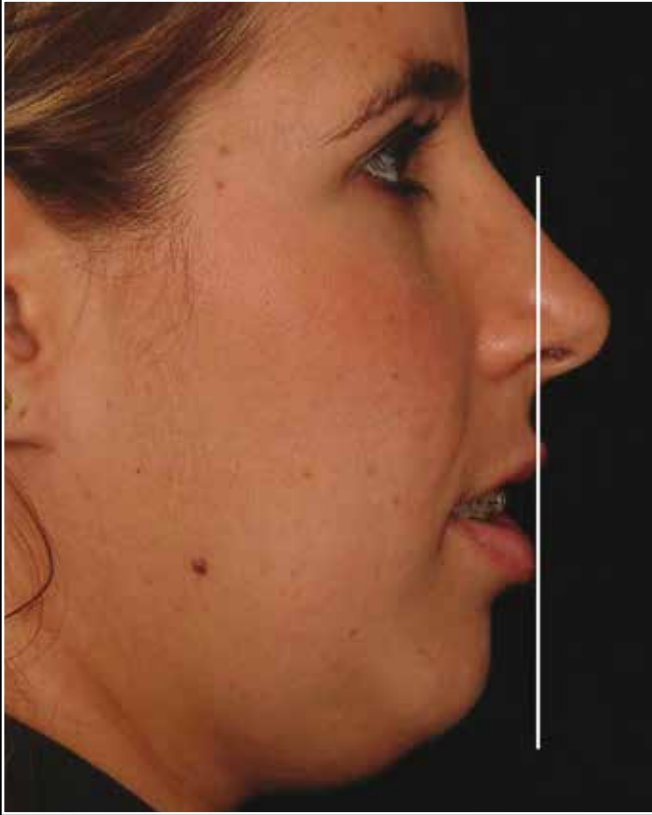

Figure 9.

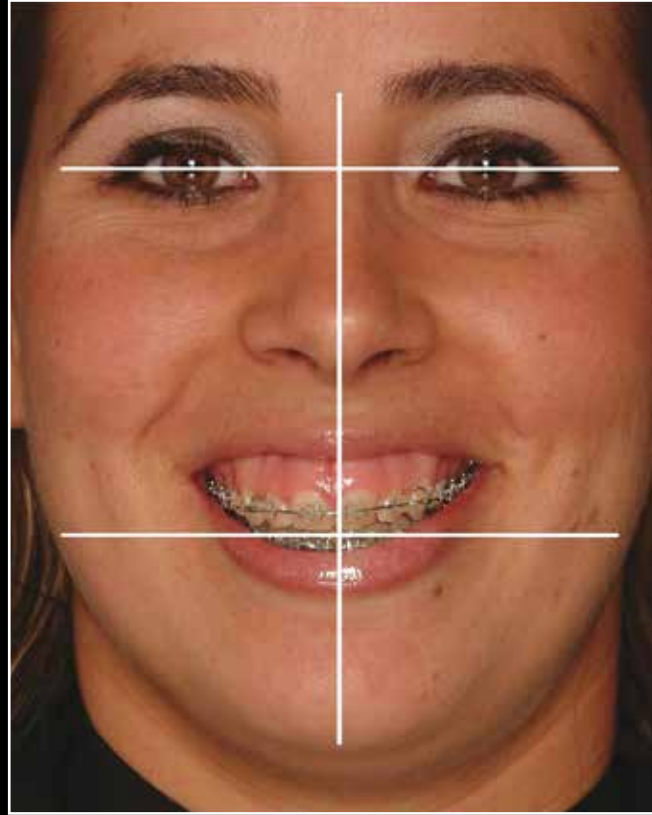


Figure 10.

Figure 11.

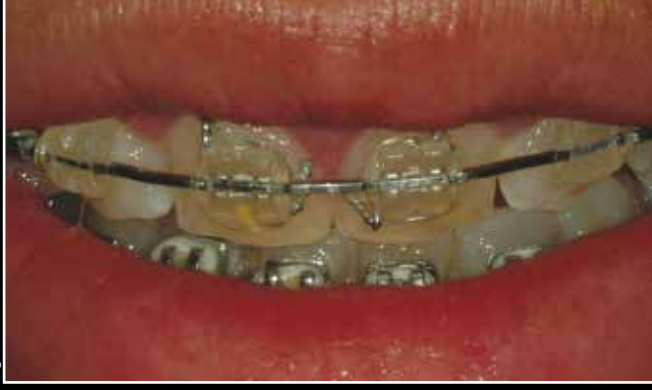

Figure 12.

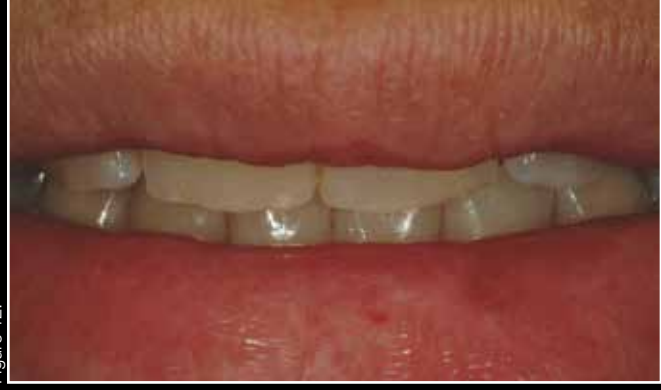

Figure 13.

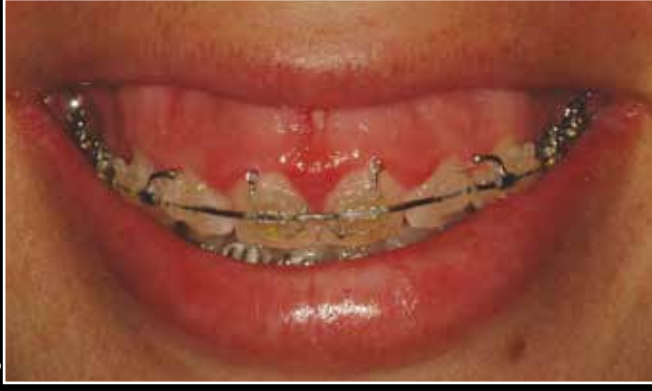

Figure 14.

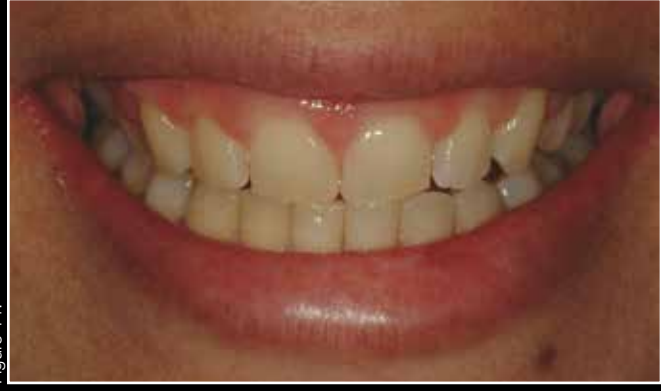

Figure 15.

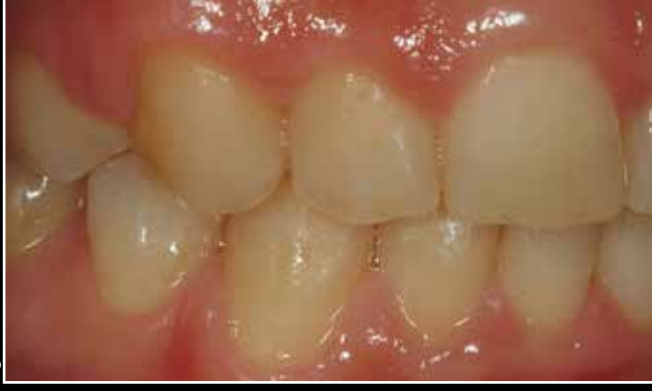

Figure 16.

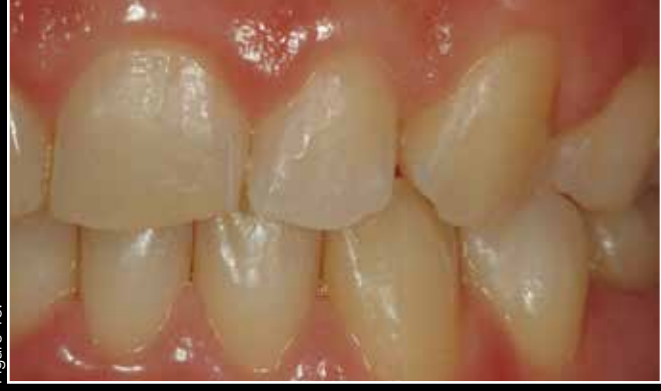

Figure 17.

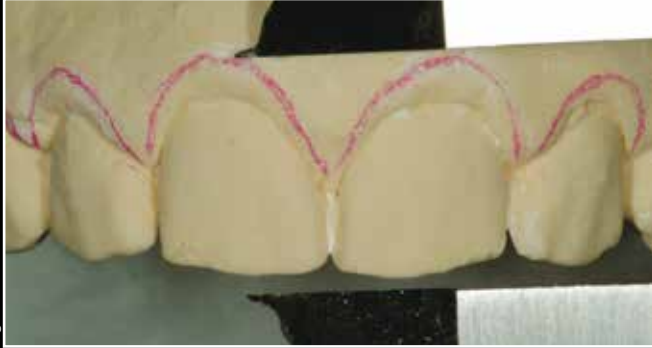
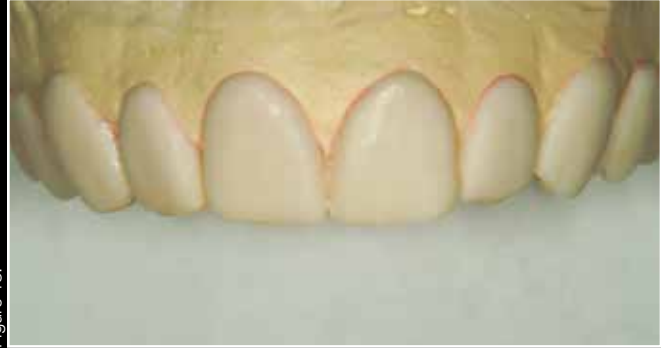

Figure 18.



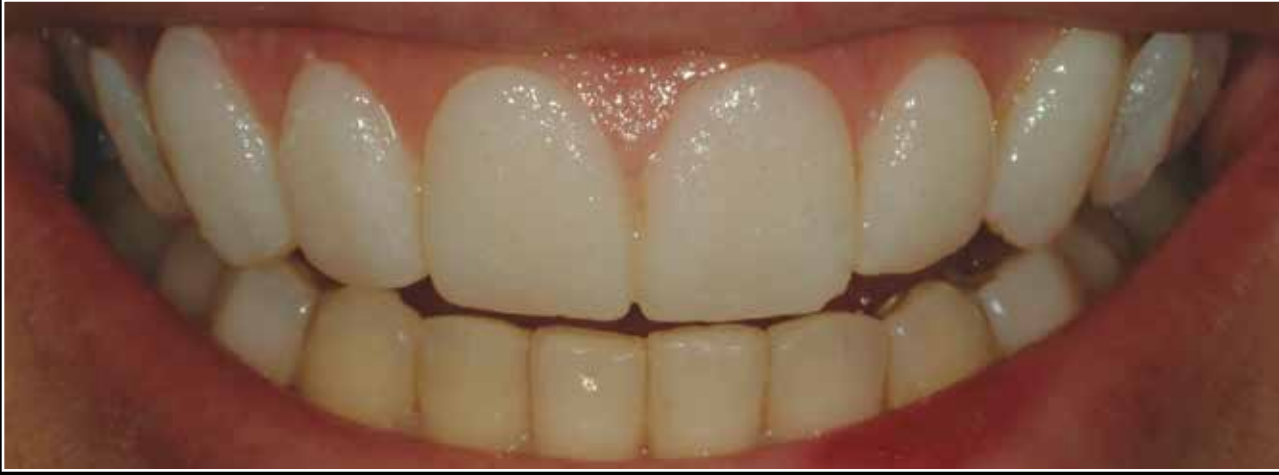

Figure 19.

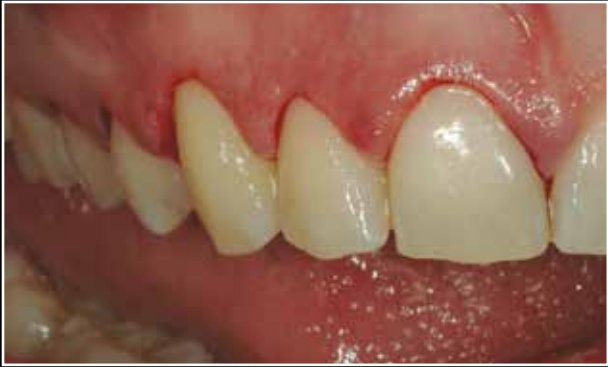

Figure 20.

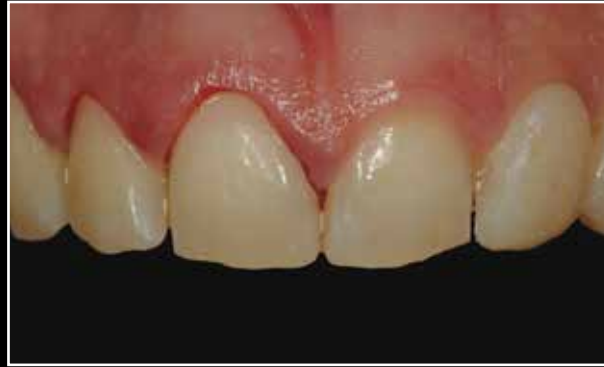

Figure 21.

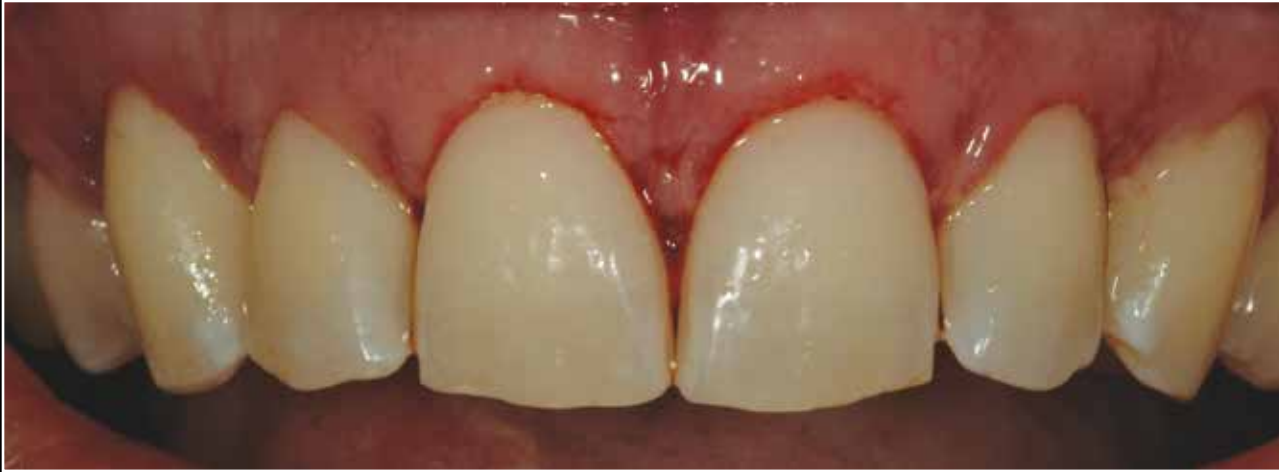

Figure 22.

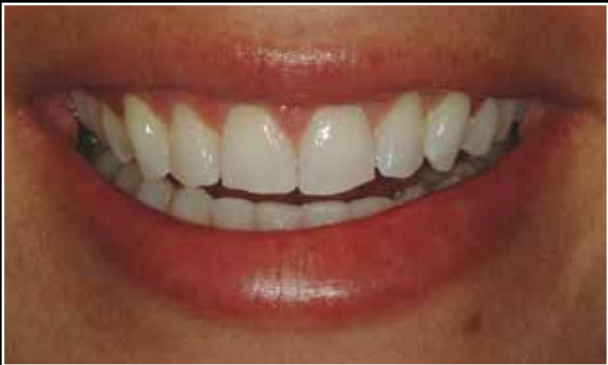

Figure 23.

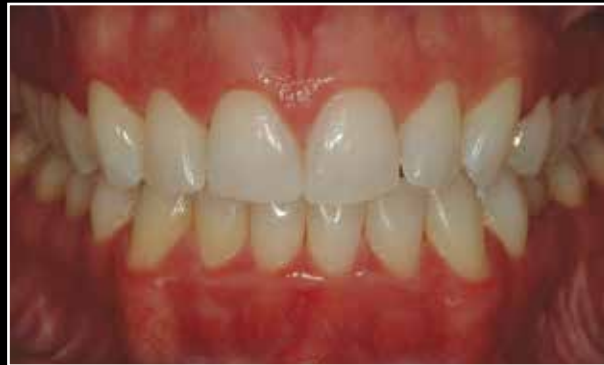

Figure 24.

Figure 25.

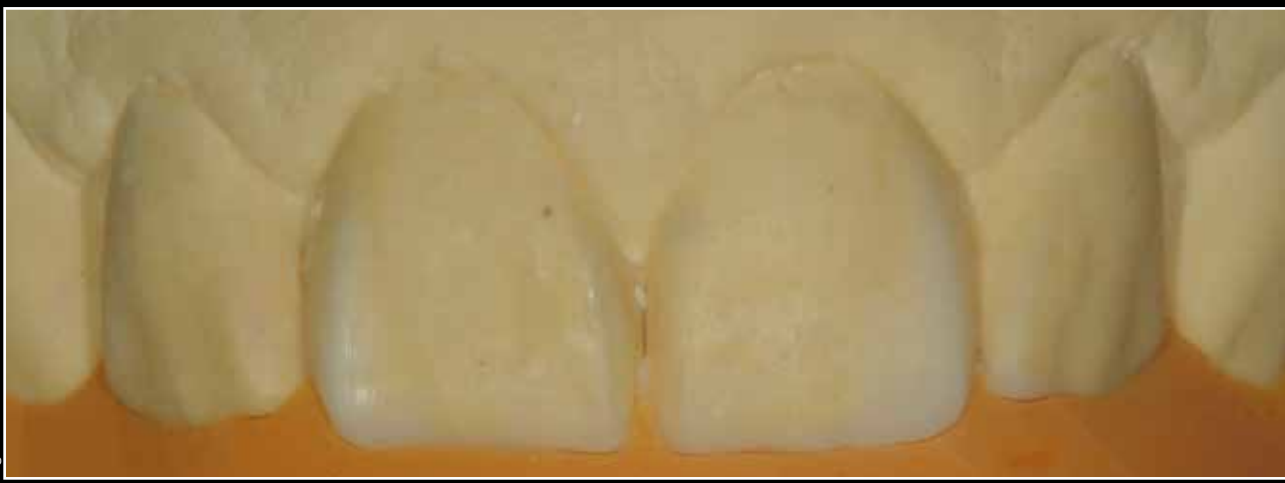

Figure 26.

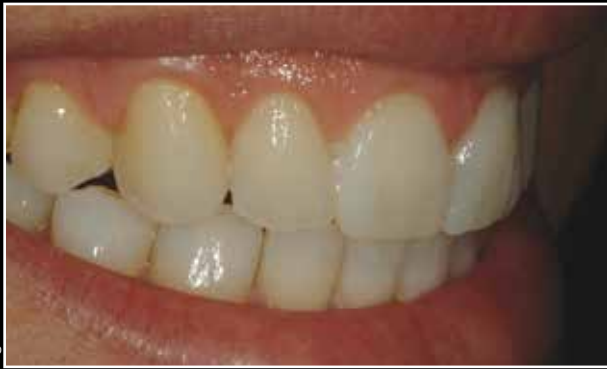

Figure 27.

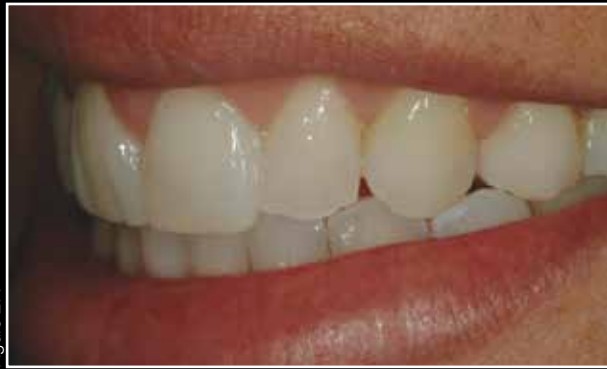

Figure 28.

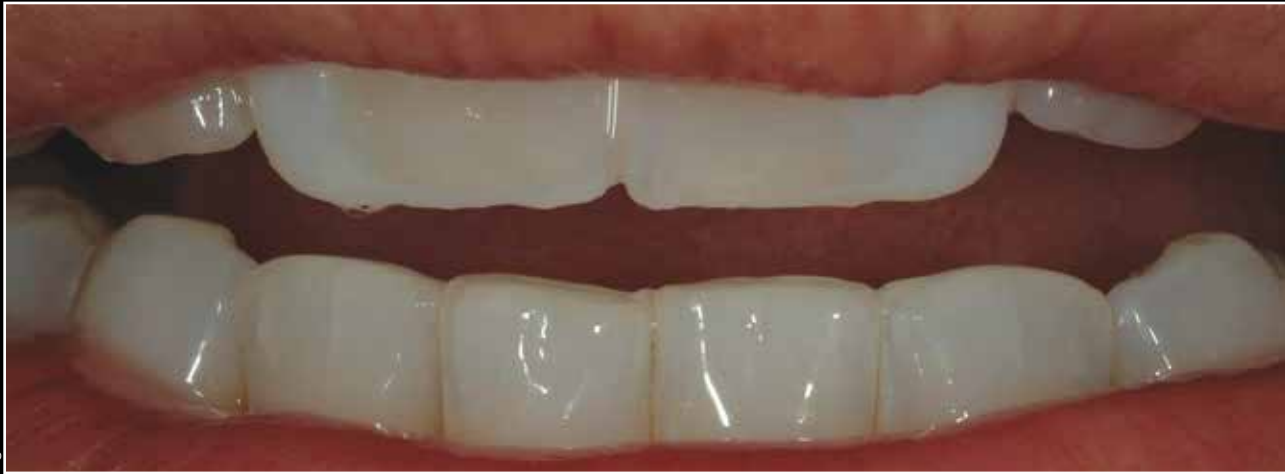

Figure 29.

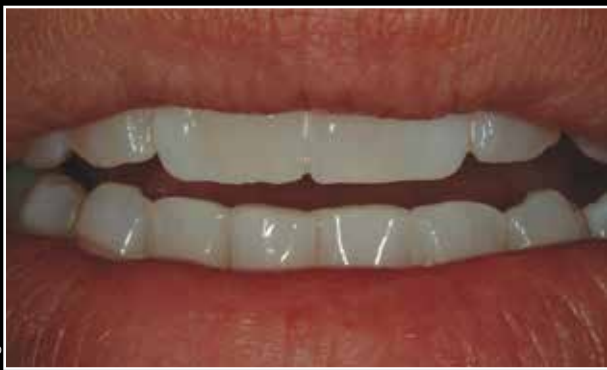
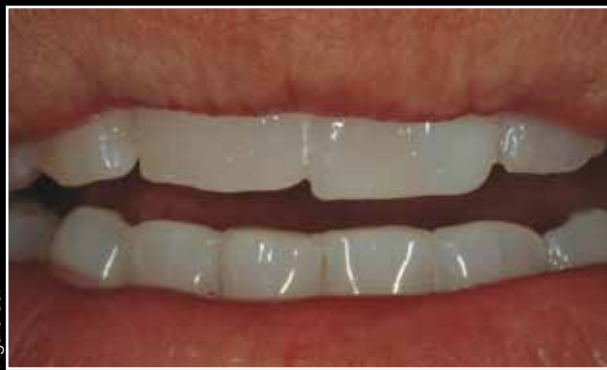
Figure 30.



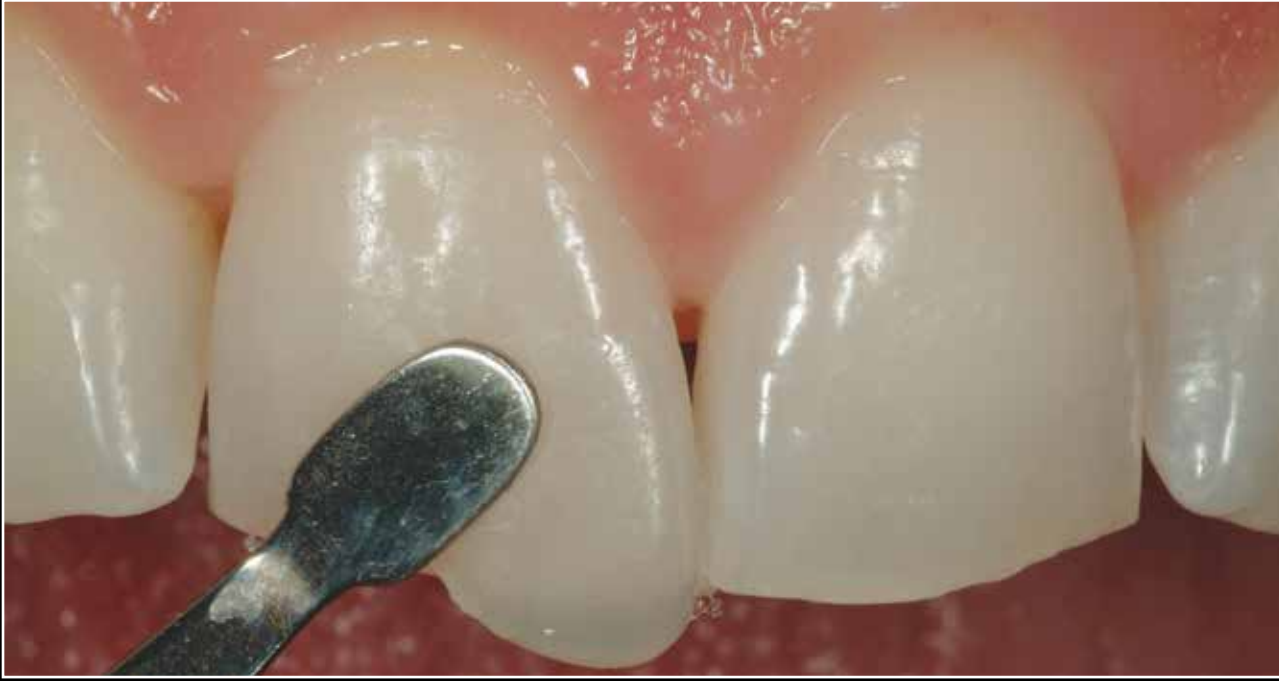

Figure 31.

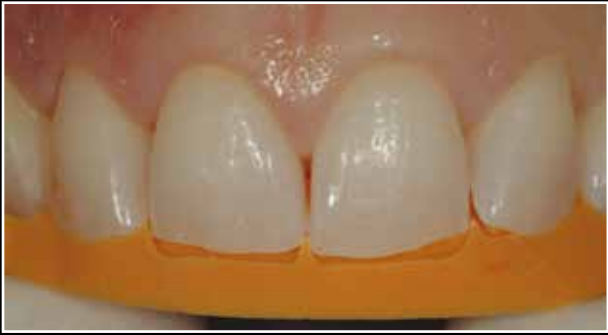

Figure 32.

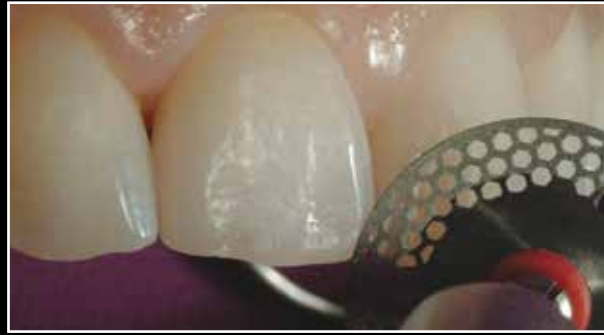

Figure 33.

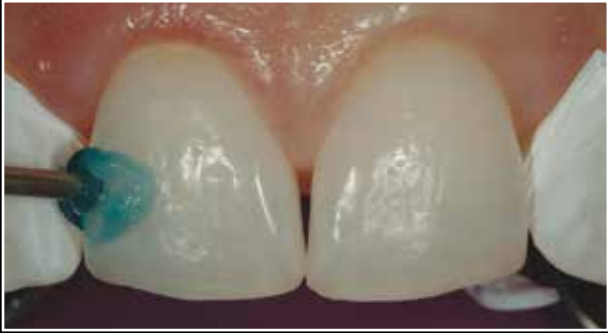

Figure 34.

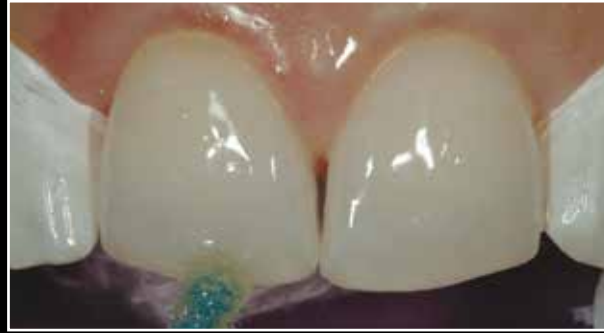

Figure 35.

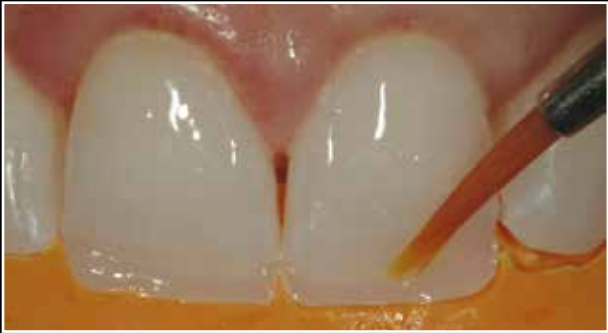

Figure 36.

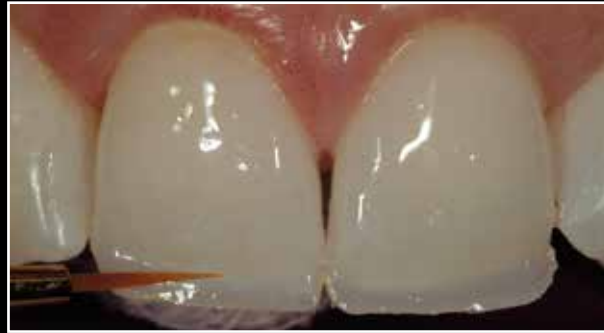

Figure 37.

Figure 38.

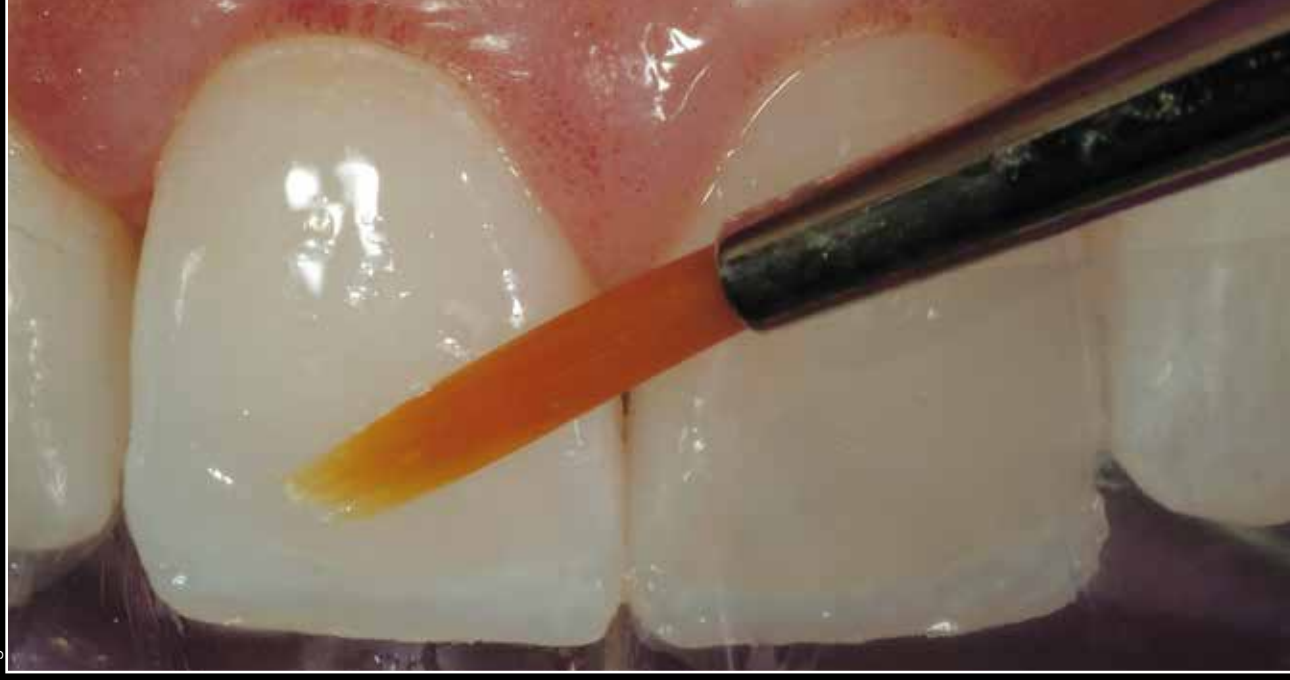


Figure 39.

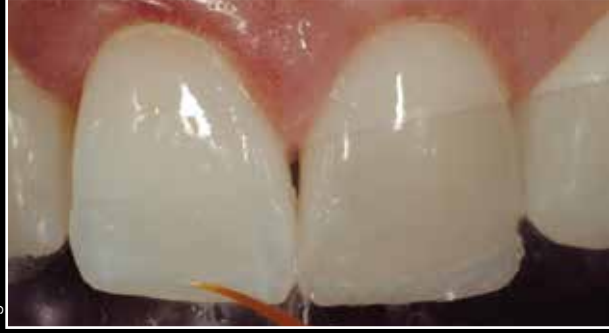

Figure 40.

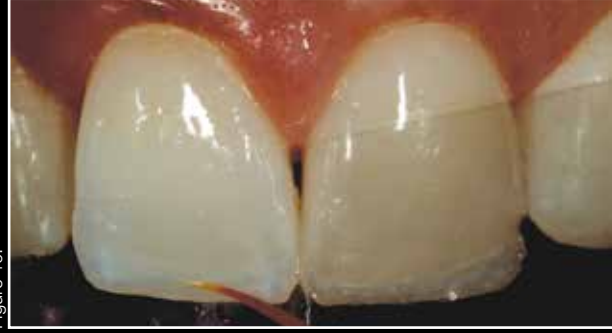

Figure 41.

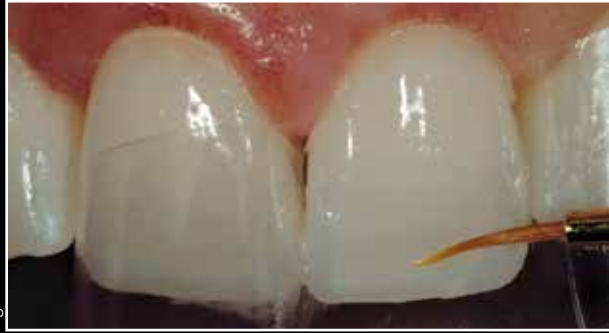

Figure 42.

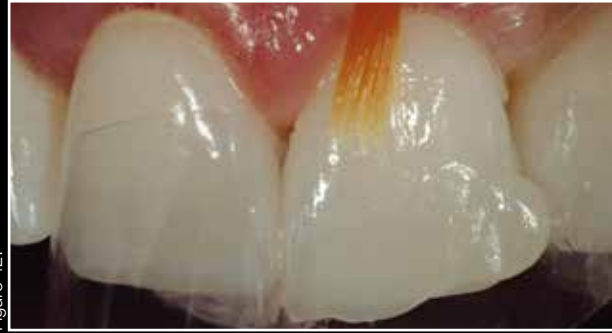

Figure 43.

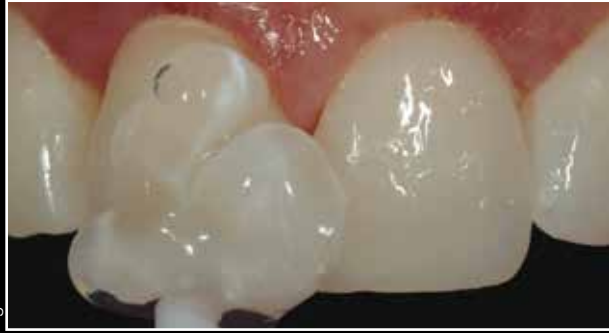
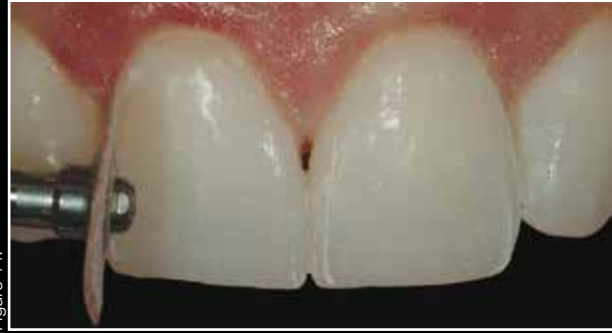
Figure 44.



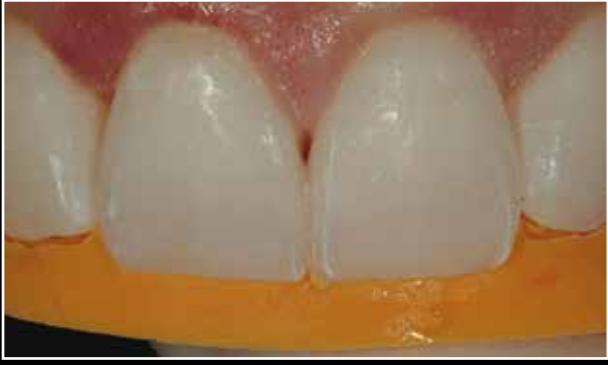

Figure 45.

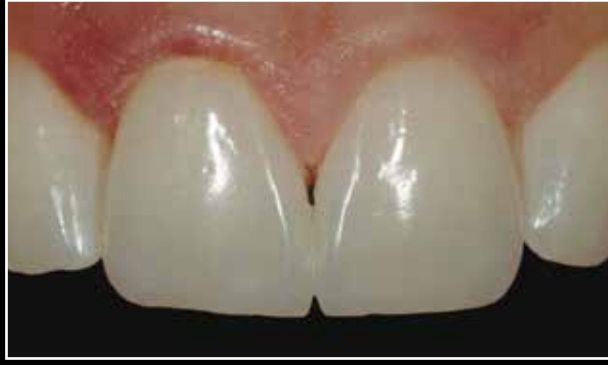

Figure 46.

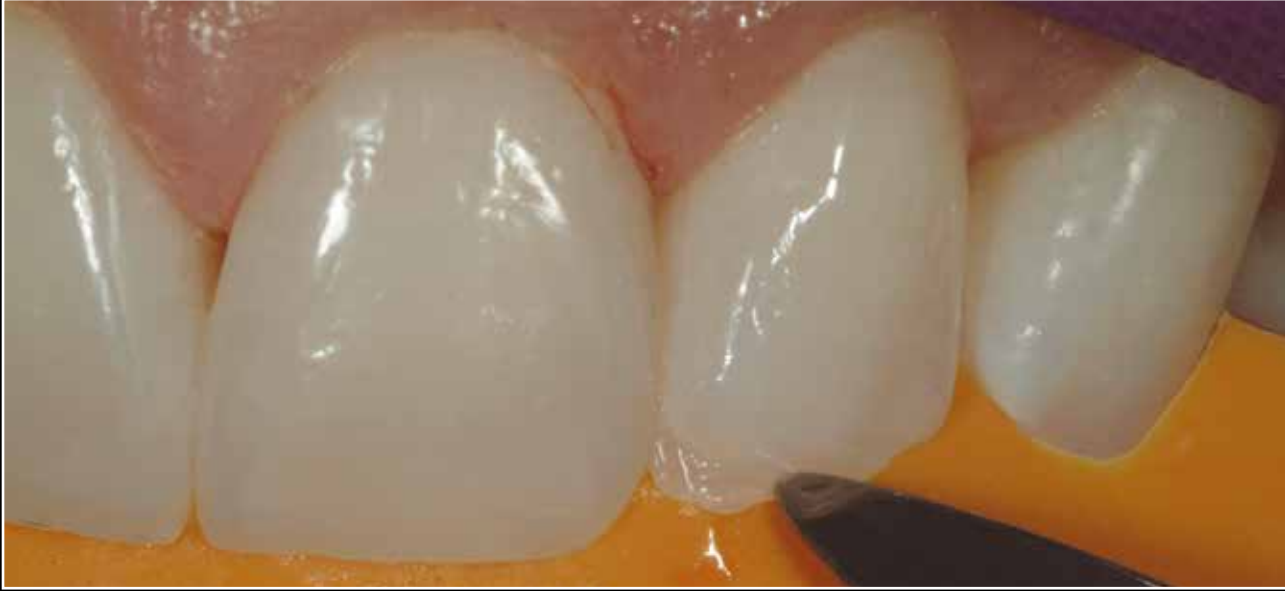

Figure 47.

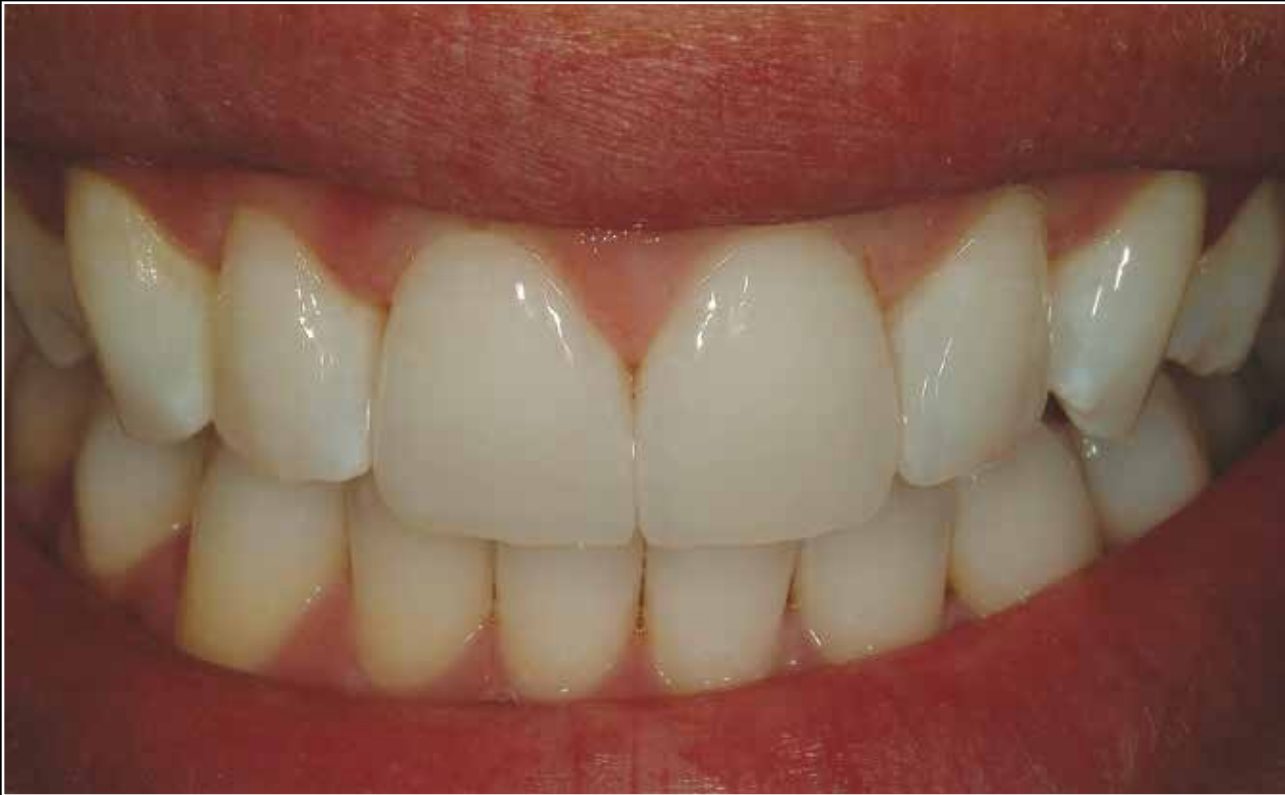

Figure 48.

Figure 49.

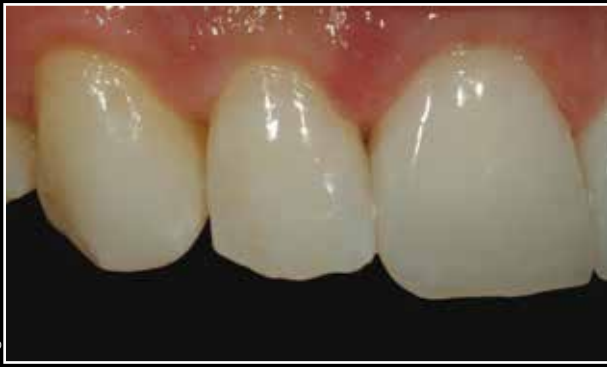

Figure 50.

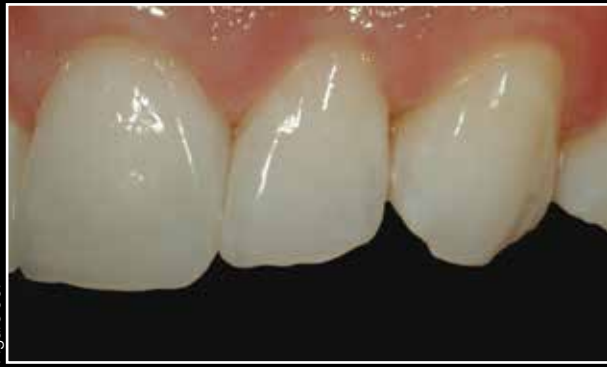

Figure 51.

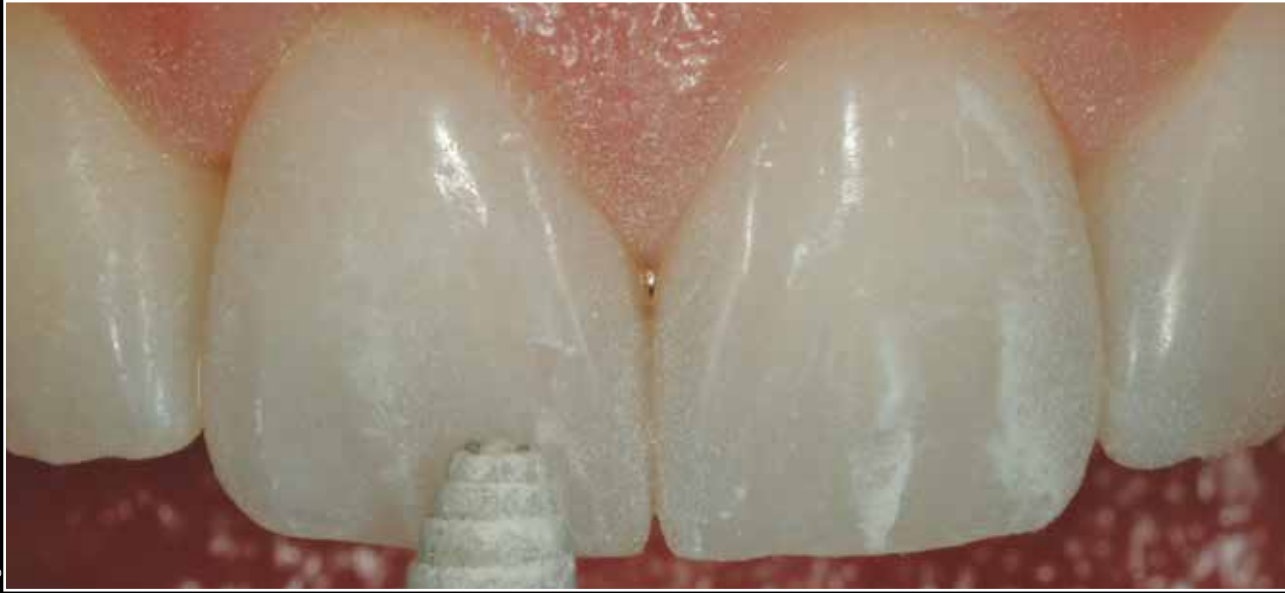
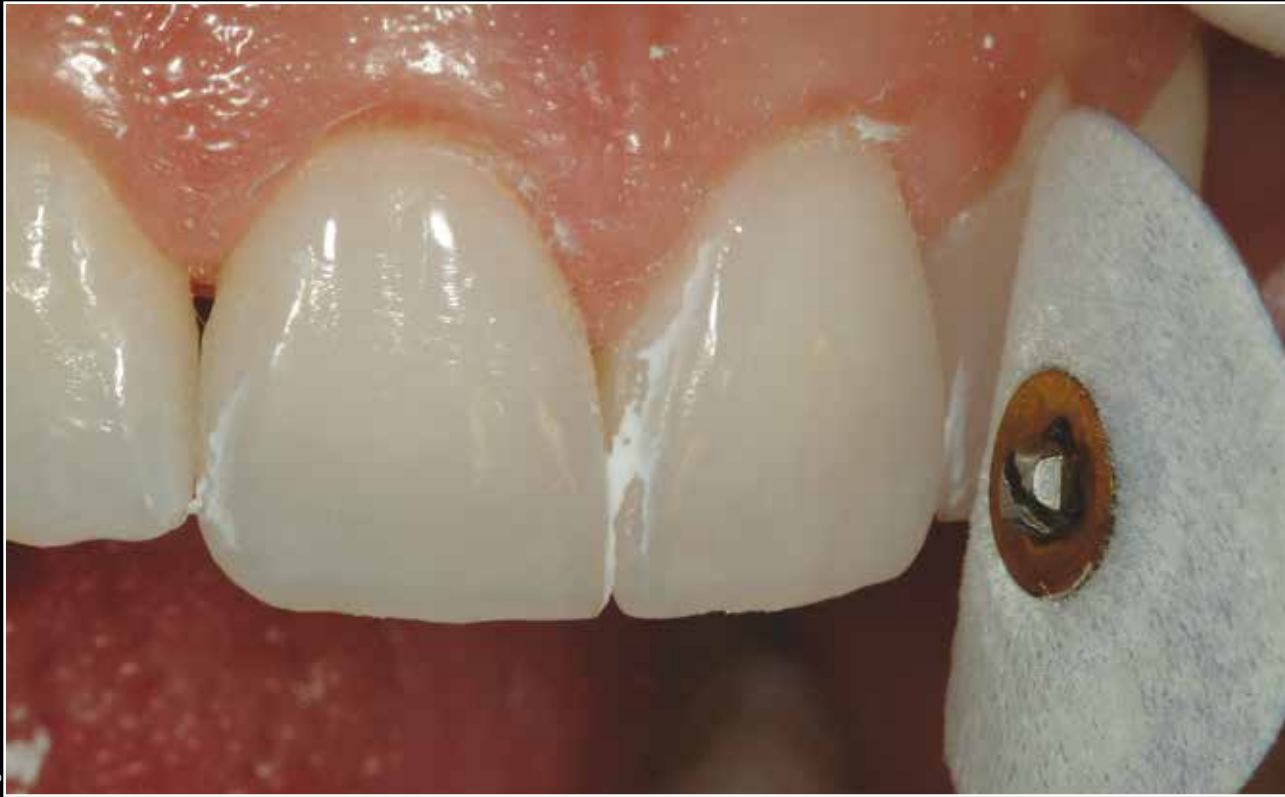
Figure 52.



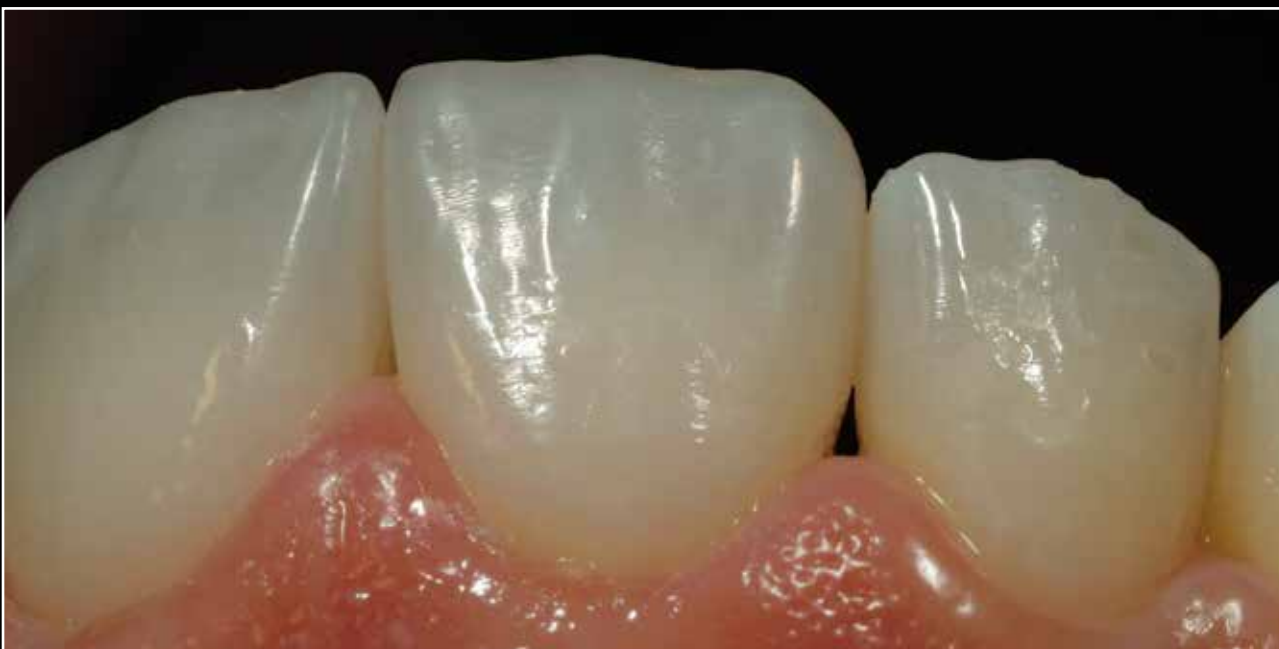

Figure 53.



Figure 54.

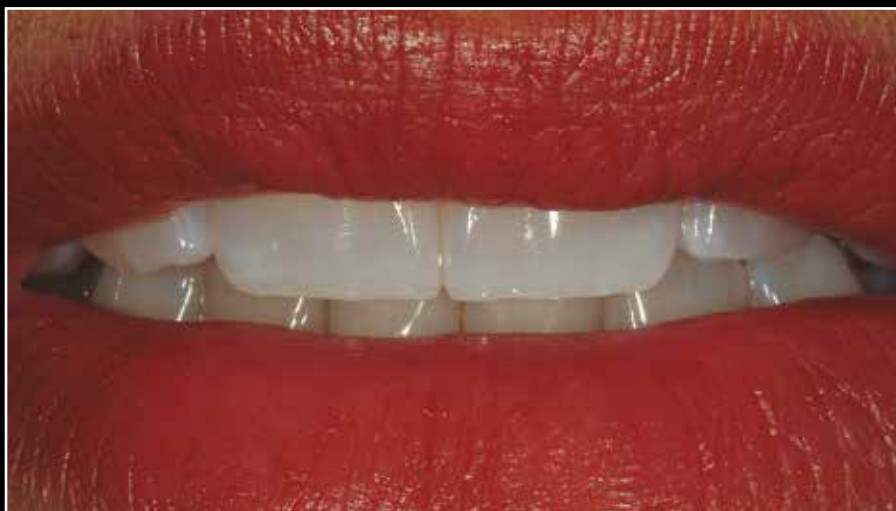

Figure 55.

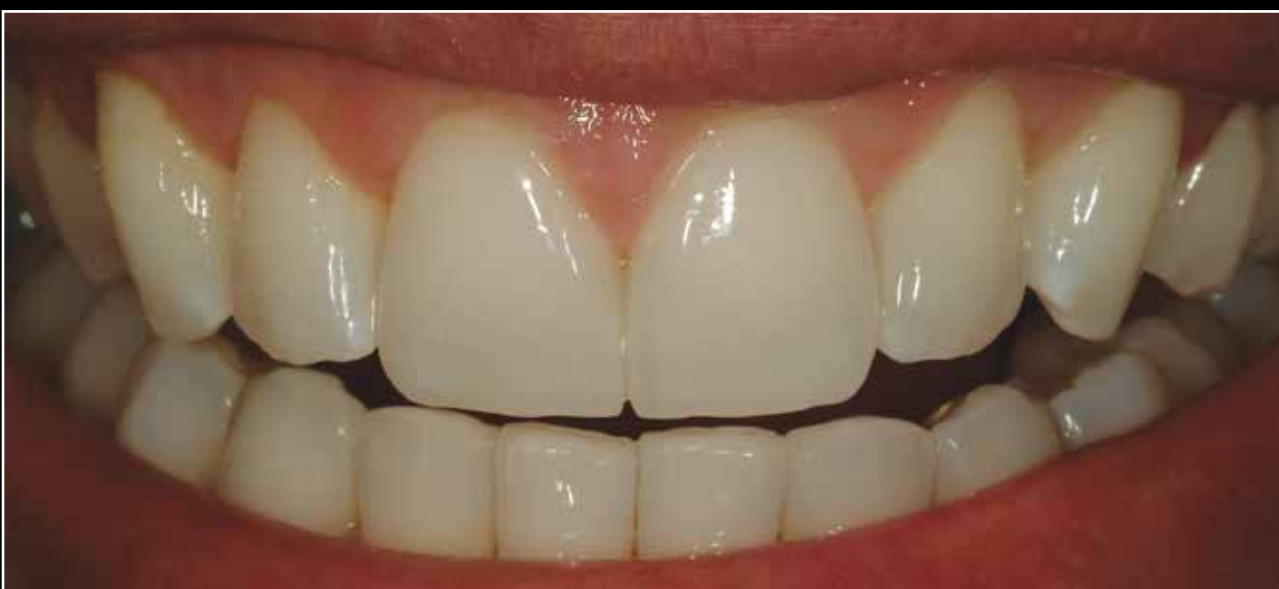

Figure 56.

Figure 57.

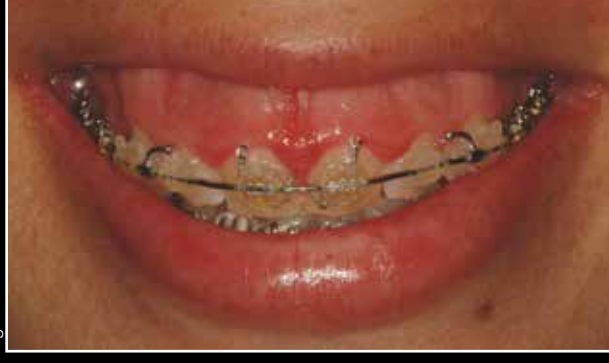

Figure 58.

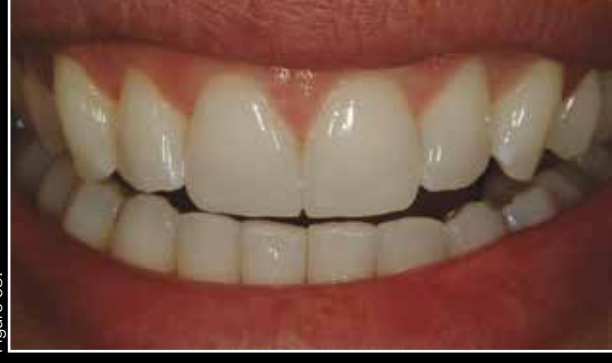

Figure 59.

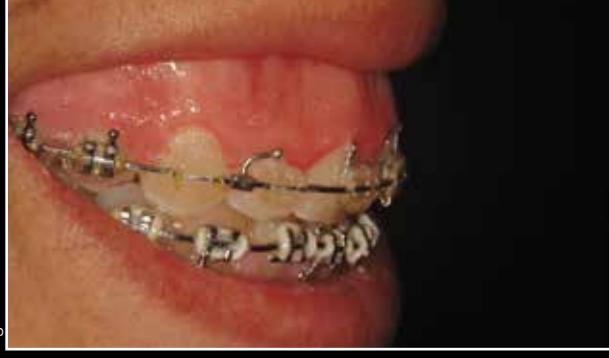

Figure 60.

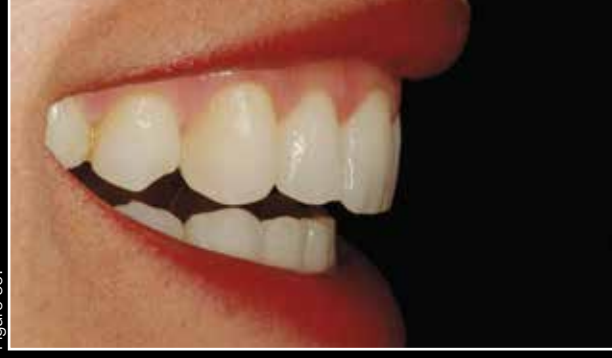

Figure 61.



Figure 62.



Figure 63.



Figure 64.

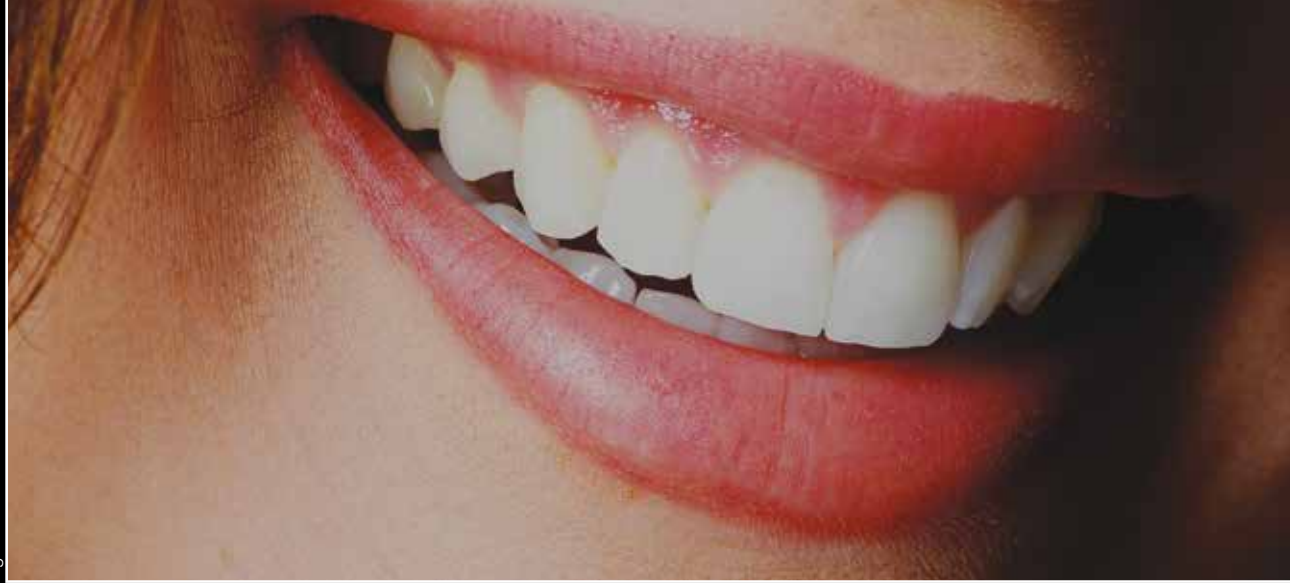




Figure 65.



Figure 66